

AFRICAN JOURNAL OF MEDICINE and medical sciences

Volume 38 Number 1

March 2009



**Editor-in-Chief
O. BAIYEWU**

**Assistant Editors-in-Chief
O. O. OLORUNSOGO
J. O. LAWOYIN**

ISSN 1116-4077

A large pericardial cyst presenting with severe chest pain: a case report and review of literature

OS Ogah¹, CO Akisanya², AO Timeyin¹, AA Adebisi³ and OA Adebo

Departments of Medicine¹ and Radiology² Federal Medical Centre, Idiaba, Abeokuta, Ogun State, Departments of Medicine³ and Surgery⁴ University College Hospital, Ibadan, Oyo State, Nigeria

Summary

Primary cysts of the pericardium are uncommon, benign developmental anomaly. Most are asymptomatic and a common incidental finding on routine chest radiograph. We report a case of large pericardial cyst presenting with severe excruciating chest pain in a Nigerian man. To the best of our knowledge, no such report has emanated from the country.

Keywords: *Pericardial cyst, cardiac tumour, chest pain*

Résumé

Les cystes primaires du péricarde sont rare, étant une anomalie de développement. La plupart n'ont pas des symptômes et détecté accidentellement après la radiographie de la poitrine. Nous présentons et rapportons le cas d'un large cyste péricardiale avec des douleurs sévères de la poitrine chez un nigérian. Dans la littérature, cette découverte est la première du genre dans le pays.

Introduction

Primary cysts of the pericardium are uncommon, benign developmental anomaly. They occur in 1/10⁵ of the general population and constitute about 6.5% of all primary heart tumours. Most are asymptomatic and a common incidental finding on routine chest radiograph [1].

We report a case of large pericardial cyst presenting with severe excruciating chest pain in a Nigerian man. No similar report has emanated from Nigeria

Case Report

A 35 year old male Nigerian presented with a week history of severe, constant and excruciating chest pain which radiated to the back. It was not related to posture or activity and only relieved by strong anal-

gesia. There was no associated fever, cough, dyspnoea or orthopnoea. He had no history of heart disease in the past although he admitted having occasional dull chest pain after a vigorous activity since childhood.

Clinical examination did not reveal any significant abnormalities. His 12-lead ECG was essentially normal. Chest radiograph showed a large homogenous soft tissue mass of slightly higher density than the cardiac silhouette which is located in the left cardio-phrenic angle. It is contiguous with the heart shadow, extends superiorly and displaces the adjoining left cardiac margin superiorly with the bulging of the left pulmonary bay. The lung fields were essentially normal and no bony abnormalities (Fig.1)

Computerised tomography scan of the chest demonstrated a rounded soft tissue mass overlying the cardiac apex and bulging of the pulmonary bay. Axial pre- and post-contrast images show a rounded hypodense mass (HU= 8-20 range) in the anterior mediastinum. The mass is seen below the level of the aortic arch and is closely related to the pericardium over the left ventricle. With contrast the mass shows enhancement in the posterior medial portion (Fig.2).

Two dimensional echocardiography revealed a large loculated hypoechoic mass posterior to the left ventricular wall (picture not shown)

Transoesophageal echocardiography facilities were not available as well as facility for serological test for hydatid disease. Our patient has been referred for surgical resection of the cyst but he declined surgery.

Discussion

Pericardial cysts are congenital abnormality but most present in adult life. Cyst of the pericardium result from an incomplete coalescence of fetal lacunae [2]. They constitute 19-25% of all mediastinal masses, and are the second commonest mediastinal cysts after bronchial cysts [2]. The tumour is most often thin walled, well defined, oval and homogenous mass.

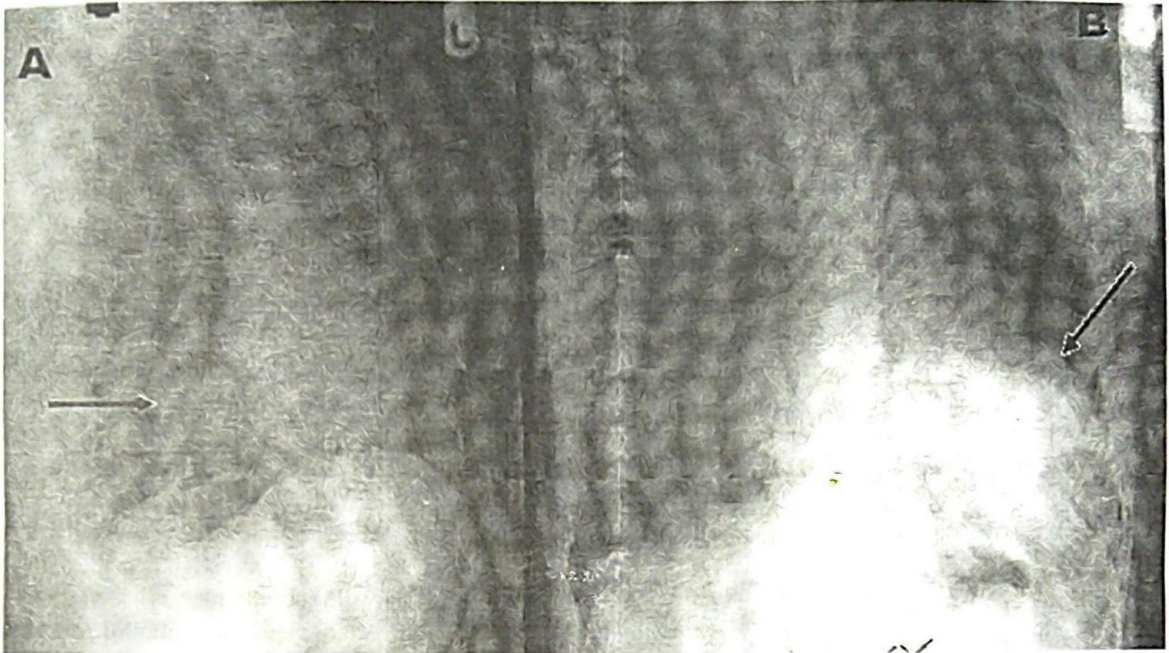


Fig. 1: Chest radiograph. A = Left lateral view, B = posterior-anterior view. Arrow points to the cyst.

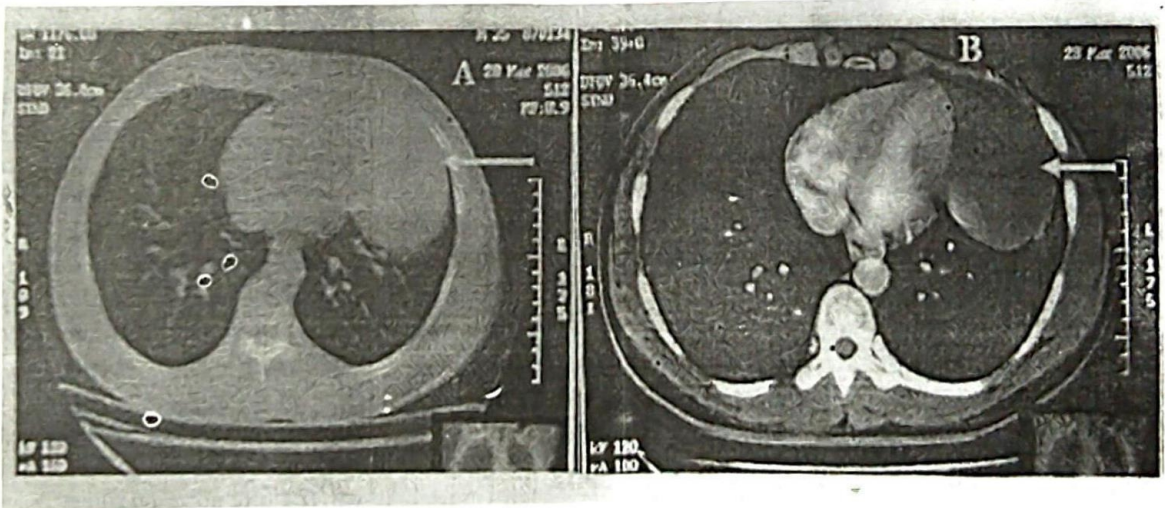


Fig. 2: Computerized tomography (CT). A = pre-contrast picture, B = post-contrast picture. Arrow points to the cyst.

They measure about 1-15cm or more [1]. Typically, they are uniloculated and lined by endothelium or mesothelium, and contain clear serous fluid. The commonest site is the right costophrenic angle (70%), followed by left costophrenic angle (22%). In 8-11%, they can be found in any of the following locations: posterior mediastinum, left hilar region, right para-tracheal area and in the neighbourhood of the aortic arch [3].

Pericardial cysts are usually detected as an incidental finding during routine medical evaluation. When symptomatic, they are as a result of pressure of the cysts on adjacent organs. In one report

symptoms of atypical chest pain, dyspnoea, and persistent cough occurred in about 33% of the subjects [4].

Once suspected on chest x-ray, CT scan of the thorax with intravenous contrast has been a common modality to make the diagnosis⁵⁻⁷. Where the exact location cannot be localised through this method; the cyst can be punctured followed by injection of a contrast medium to make the definitive diagnosis [5]. This may also serve as a way of treatment of some cases [5].

The work of Hynes *et al* showed the potential role of two-dimensional echocardiography

in the diagnosis of pericardial cyst [2]. It is believed that "echocardiography is a superior non-invasive modality to delineate the exact location of a pericardial cyst and differentiate a cyst from other potential diagnoses such as prominent fat pad, left ventricular aneurysm, prominent left atrial appendage and solid tumours [8]"

Colour and Doppler echocardiography is useful in differentiating a pericardial cyst from other vascular lesions such as coronary artery aneurysm [8]

In cases where thoracic echocardiography is insufficient in delineating the diagnosis, transoesophageal echocardiography can be useful [9]. It can also help in identifying cases in atypical locations as well as differentiating it from other posterior located lesions [9]. Other workers have also showed the potential role of echocardiography in the diagnosis of this condition [9-12].

Other differential diagnosis include: mediastinal or diaphragmatic tumours [13], tumours of the heart or pericardium and foramen of Morgagni diaphragmatic hernia [2].

Pericardial cysts usually follow a benign course in majority of cases. Some of the reported complications are cardiac compression with haemodynamic disturbances [14,15], rupture of the cyst [16], ventricular wall erosion [17], superior venacava erosion [18] and cyst infection [19]. Others are atrial fibrillation [20], myocardial infarction [21] and sudden cardiac death after a stress test [22].

Chest pain is a rare complication and it is said to be due to torsion of the cyst [23,24].

Most authorities recommend surgical excision of pericardial cyst only in symptomatic cases [25]. It is advocated that asymptomatic cases be managed conservatively with close follow-up [25].

Minimally invasive thoracoscopic resection of the cyst is a good alternative option to open surgical resection because it minimizes surgical trauma and postoperative pain, has a shorter recovery period and a better cosmetic outcome [26].

Percutaneous aspiration of cyst contents is another alternative to surgical resection in symptomatic patients. In one review, a three-year follow-up study of post percutaneous resection showed no recurrence in four out of six patients [1]

Spontaneous resolution of a pericardial cyst has been reported in few cases managed conservatively, the probable mechanism being cyst rupture [27].

In conclusion, primary cysts of the pericardium are uncommon, benign developmental anomaly. Most are asymptomatic and a common incidental finding on routine chest radiograph. Chest pain is a rare complication and it is said to be due to torsion of the cyst

References

1. Stoller JK, Shaw C and Matthay RA. Enlarging, atypically located pericardial cyst. Recent experience and literature review. *Chest* 1986; 89(3): 402-406.
2. Hynes JK, Tajik AJ, Osborn MJ, Orszulak TA and Seward JB. Two-dimensional echocardiographic diagnosis of pericardial cyst. *Mayo Clin Proc* 1983; 58(1):60-63.
3. Nijveldt R, Beek AM, van Gorp JM and van Rossum AC. Pericardial cyst. *Lancet* 2005; 365 (9475): 1960.
4. Feigin DS, Fenoglio JJ, McAllister HA and Madewell JE. Pericardial cysts. A radiologic-pathologic correlation and review. *Radiology* 1977; 125(1):15-20.
5. Parienty RA, Fontaine Y, Dufour G. Transformation of a pericardial cyst observed on long-term follow-up. *J Comput Tomogr* 1984; 8(2): 125-128.
6. Omrani GR, Kargar F and Aazami MH. Intra-pericardial hydatid cyst seen by dynamic computed tomography. *Eur J Cardiothorac Surg* 2006; 30(5): 805.
7. Kaimal KP. Computed tomography in the diagnosis of pericardial cyst. *Am Heart J* 1982; 103 (4 Pt 1): 566-567.
8. Patel J, Park C, Michaels J, Rosen S and Kort S. Pericardial cyst: case reports and a literature review. *Echocardiography* 2004; 21(3): 269-272.
9. Padder FA, Conrad AR, Manzar KJ, Thayapran N, Jonas EE and Freeman I. Echocardiographic diagnosis of pericardial cyst. *Am J Med Sci* 1997; 313(3): 191-192.
10. Rosas-Munive E, Peralta-Rosado H, Muro-Calderon CJ and Diaz-Brito A. Echocardiographic Diagnosis of a Pericardial Cyst: Loculated Pericardial Effusion. *Echocardiography* 1997; 14(6 Pt 1):629-630.
11. Felner JM, Fleming WH and Franch RH. Echocardiographic identification of a pericardial cyst. *Chest* 1975; 68(3): 386-387.
12. Munoz Gil J, Chorro FJ, Martinez-Leon J, *et al.* [Echocardiography in the diagnosis of a pericardial cyst. Presentation of a case]. *Rev Esp Cardiol* 1985; 38(4): 298-299.

13. Adebonojo SA, Grillo IA, Falase AO, Aghadiuno PU. Middle mediastinal thymoma simulating pericardial cyst. *Int Surg* 1977; 62(6-7): 343-345.
14. Bandeira FC, de Sa VP, Moriguti JC, et al. Cardiac tamponade: an unusual complication of pericardial cyst. *J Am Soc Echocardiogr* 1996; 9(1): 108-112.
15. Shiraishi I, Yamagishi M, Kawakita A, Yamamoto Y and Hamaoka K. Acute cardiac tamponade caused by massive hemorrhage from pericardial cyst. *Circulation* 2000; 101(19): E196-197.
16. King JF, Crosby I, Pugh D and Reed W. Rupture of pericardial cyst. *Chest* 1971; 60(6): 611-612.
17. Chopra PS, Duke DJ, Pellett JR, Rahko PS. Pericardial cyst with partial erosion of the right ventricular wall. *Ann Thorac Surg* 1991; 51(5): 840-841.
18. Mastroroberto P, Chello M, Bevacqua E, Marchese AR. Pericardial cyst with partial erosion of the superior vena cava. An unusual case. *J Cardiovasc Surg (Torino)* 1996; 37(3): 323-324.
19. Kochegarov AA, Azizov IA. [A large infected celomic pericardial cyst]. *Grudn Khir* 1971; 13(5): 110-111.
20. Vlay SC, Hartman AR. Mechanical treatment of atrial fibrillation: removal of pericardial cyst by thoracoscopy. *Am Heart J* 1995; 129(3): 616-618.
21. Ispas R, Ruicanescu I, Marosin C. [Pericardial hydatid cyst and acute myocardial infarct]. *Rev Med Interna Neurol Psihiatr Neurochir Dermatovenerol Med Interna* 1984; 36(3): 283-287.
22. Fredman CS, Parsons SR, Aquino TI and Hamilton WP. Sudden death after a stress test in a patient with a large pericardial cyst. *Am Heart J* 1994; 127(4 Pt 1): 946-950.
23. Ileri M, Hisar I, Atak R, Senen K, Aras D and Buyukasik N. A pericardial hydatid cyst masquerading as acute inferolateral myocardial infarction—a case report. *Angiology* 2005; 56(5): 637-640.
24. Mogensen CB and Petersen HO. [Pericardial cyst—a rare cause of thoracic pain]. *Ugeskr Laeger* 2003; 165(2): 137-138.
25. Abad C, Rey A, Feijoo J, Gonzalez G and Martin-Suarez J. Pericardial cyst. Surgical resection in two symptomatic cases. *J Cardiovasc Surg (Torino)* 1996; 37(2): 199-202.
26. Szinicz G, Taxer F, Riedlinger J and Erhart K. Thoracoscopic resection of a pericardial cyst. *Thorac Cardiovasc Surg* 1992; 40(4): 190-191.
27. Kruger SR, Michaud J and Cannom DS. Spontaneous resolution of a pericardial cyst. *Am Heart J* 1985; 109(6): 1390-1391.

Received: 15/02/08

Accepted: 10/02/09